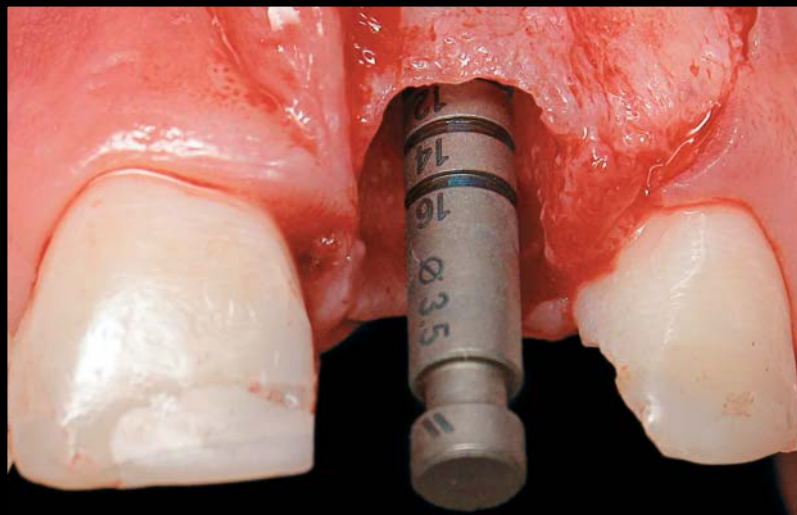


GUIDED BONE REGENERATION USING AN ALLOGRAFT MATERIAL: REVIEW AND CASE PRESENTATIONS

Monish Bhola, DDS, MSD*
 Bassam M. Kinaia, DDS*
 Katy Chahine, DDS*



Post extraction sites may have residual ridge deformities with insufficient bone present for future implant placement. This presents a challenge to the clinician attempting to obtain optimum results. To predictably augment these areas and obtain aesthetically pleasing results, bone grafting may be required. Guided bone regeneration with an allograft material is a predictable means by which to solve this challenge. This article describes three case presentations utilizing an allograft material for bone regeneration prior to implant placement.

Learning Objectives:

This article discusses the use of an allograft material for predictable bone regeneration prior to implant placement. Upon completing this article, the reader should:

- Recognize the role of bone grafting materials on implant longevity and retention.
- Understand the importance of developing sufficient bone structures with minimal patient discomfort or trauma.

Key Words: guided bone regeneration, allograft, implant, bone graft

*University of Detroit, School of Dentistry, Department of Periodontology and Dental Hygiene, Detroit, Michigan.

Monish Bhola, DDS, MSD, University of Detroit, School of Dentistry, Department of Periodontology and Dental Hygiene, 2700 Martin Luther King Jr. Blvd, Detroit, MI 48208
 Tel: 313-494-6663 • E-mail: monishbhola@hotmail.com

Bone grafts have long been employed for the treatment and correction of periodontal defects and ridge deficiencies. The rationale behind bone graft use originates from the osteogenic, osteoinductive, or osteoconductive properties possessed by the grafting materials.¹ Osteogenic material stimulates new bone formation, as bone-forming cells are contained within the graft itself. Osteoinductive materials stimulate bone formation in the surrounding tissue immediately adjacent to the graft. In contrast, osteoconductive materials serve as scaffolds for bone growth within existing bony walls.²

Sources of bone grafts include autografts, allografts, xenografts, and alloplasts. Autografts are obtained from extra- or intraoral sites and implanted in the same patient from whom they are obtained. Although the use of autografts often results in the redevelopment of periodontal attachment, significant morbidity is associated with their placement (eg, ankylosis, root resorption).³ Allografts were developed using materials harvested from cadavers of the same species to circumvent the morbidity associated with autogenous bone grafts.⁴ Application of this grafting technique elicited minimal postoperative pain and clinical signs of immunologic rejection. In addition to allograft materials, xenografts containing tissues transferred from one species to another and synthetic alloplasts have been incorporated to treat periodontal defects.

GBR using Autograft and Allograft *Principles Adapted from GTR*

Four different cell types have been suggested that dictate the type of healing encountered in periodontal tissue.⁵ These cells may originate from the gingival epithelial tissue, lamina propria of connective tissue, bone, or periodontal ligament. Cells derived from periodontal ligaments and bones have the potential to heal by true regeneration, as opposed to cells from the lamina propria of the gingiva or gingival epithelial tissue.⁵ Understanding barrier-mediated selective cell repopulation gave rise to the concept of epithelial exclusion to restore lost periodontal tissue and obtain new attachment around teeth. This same model is applied in guided bone regeneration (GBR), which regenerates lost alveolar bone and promotes hard tissue formation by employing a barrier. It is used to regenerate bone in preparation for implant-site development (eg, in ridge augmentation, around exposed threads of implants). As techniques evolved, predictable intraoral GBR was developed for localized ridge augmentation and repair of dehiscence around implants.^{6,7}

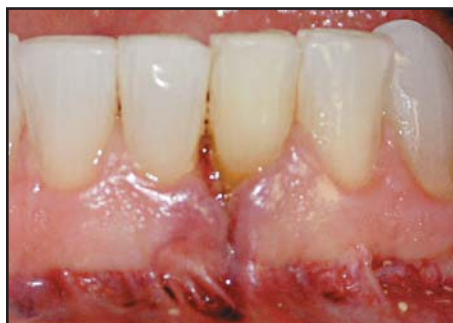

Figure 1. Case 1. Preoperative view showing a non-healing scar by tooth #24, six months following endodontic surgery.

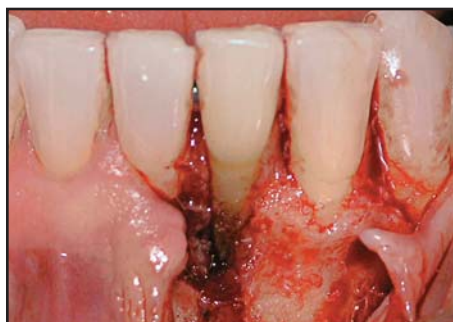

Figure 2. Anterior view during surgery, demonstrating facial dehiscence of the mandibular left central incisor.

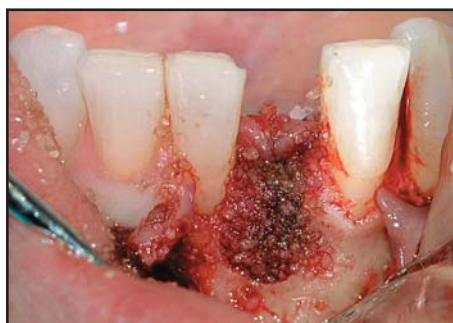

Figure 3. Anterior view following application of the allograft in the defect site.

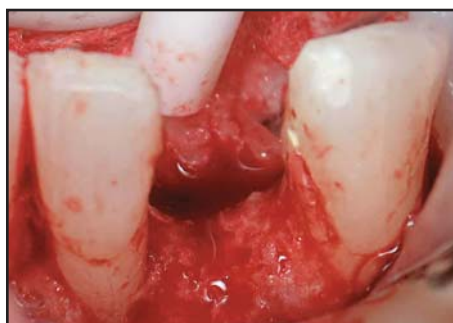

Figure 4. Sufficient bone volume in order to facilitate implant placement was evidenced six months following initial treatment.

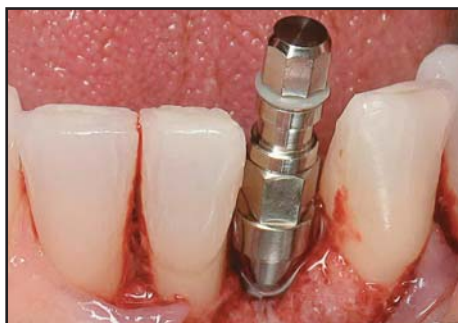

Figure 5. Facial view following successful placement of the dental implant.

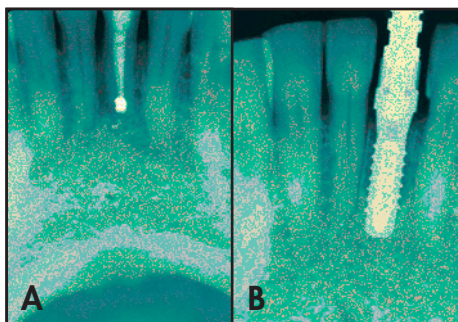


Figure 6A. Preoperative periapical radiograph of the failed apicoectomy. **6B.** Radiographic appearance following the implant placement.

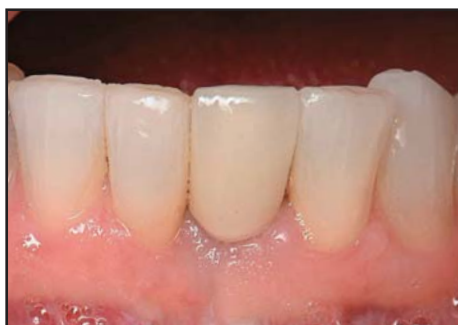

Figure 7. Postoperative appearance of the restored implant, showing complete healing.

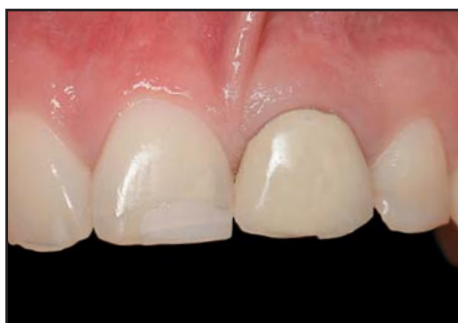

Figure 8. Case 2. Preoperative view of the fractured maxillary left central incisor.

In 1993, Buser et al attempted to augment local ridge deficiency in the maxilla and presented two case reports. In the first case, tenting mini-screws were employed for space maintenance in the anterior region, with simultaneous implant placement. In the second case—also in the anterior dentition—the mini-screws were used in conjunction with staged implant placement following nine months of healing. In both cases, GBR resulted in predictable results and implant survival.⁶ Further research was performed employing mini-screws and intramarrow penetrations in the mandibular region. It is noteworthy that the authors emphasized obtaining primary closure for predictable results.⁷

Although autogenous block grafts have been employed in GBR, there is associated neurological and vascular risk with their use. Therefore, the use of a particulate allograft may minimize such risks. Fugazotto et al presented a report of 1,503 immediate implants in fresh extraction sockets requiring GBR. They compared use of membranes (Gore-Tex, Flagstaff, AZ) over demineralized freeze-dried bone allograft (DFDBA), freeze-dried bone allograft (FDBA), an equal combination of these, to DFDBA combined with equal parts of resorbable tricalcium phosphate. Comparison of findings at the time of clinical re-entry demonstrated an overall success rate of 97.0% in the treatment of dehiscid or fenestrated implants or fixtures placed in immediate extraction sockets.⁸ Moreover, Simion et al conducted a controlled human clinical study to evaluate the predictability of different bone grafts for GBR around implants.⁹ Autografts, DFDBA, and FDBA predictably regenerated bone around implants. Shanaman et al evaluated retrospectively the significance of cases in which no graft was employed compared to cases using DFDBA and FDBA bone grafts in 237 regenerated sites. They found that FDBA was superior in obtaining predictable results followed by combination of FDBA and DFDBA, then DFDBA, and finally no graft.¹⁰ Therefore, materials that result in slower resorption (eg, FDBA) are generally advantageous for use in GBR procedures.

Guided bone regeneration is also used to correct bony defects (eg, fenestrations, dehiscence defects) around dental implants. Dahlin et al studied guided bone regeneration around 55 dental implants placed with membranes at 15 fenestrations and 40 dehiscence defects. The defect height was reduced from 4.7 mm to 1.1 mm. The researchers concluded that GBR is a predictable treatment for dental implants placed in sites with insufficient bone.¹¹

Resorbable versus Non-Resorbable Membranes

In comparing resorbable and non-resorbable membranes, there is no evidence from available randomized clinical trials supporting superior success with one or the other.¹² Some evidence indicates that a non-resorbable membrane has demonstrated increased predictability in permitting bone growth around dental implants when compared to sites treated without a membrane, and a resorbable membrane over a bone graft may allow healing with fewer infections than a non-resorbable membrane.¹² Simion et al evaluated the use of resorbable (PLA/PGA) versus non-resorbable membranes (e-PTFE) for guided bone regeneration. Seven defects were treated with PLA/PGA membranes, five were treated with e-PTFE membranes, and four were left untreated. After six months of healing, very little or no bone formation was detected in control specimens. The PLA/PGA membranes produced some bone regeneration when compared to control sites, but to a lesser extent compared to e-PTFE sites.¹³ Contrarily, Marinucci et al mentioned collagen and poly DL-lactide resorbable membranes stimulated DNA synthesis more than e-PTFE. Therefore, they may promote bone regeneration through their activity on osteoblasts.¹⁴ Thus, although non-resorbable barriers present the gold standard in regeneration therapy, bioabsorbable collagen membranes may simplify the surgical technique and make it more predictable. Llambés et al attempted vertical ridge augmentation on 11 patients at the time of implant placement. Autogenous bone grafts with collagen membrane were employed to achieve bone regeneration. Sites were re-entered at four to six months, and healing abutments were placed. The results exhibited 3-mm gain in bone height at re-entry, which represented 83% of the exposed implant. One year post-loading, the implants showed a mean marginal bone loss of 1.4 mm. The researchers concluded that collagen membranes have the potential to promote vertical ridge augmentation when used with autogenous bone at the time of implant placement.¹⁵

Bioresorbable membranes may also be used for horizontal, as well as vertical, ridge augmentation. Von Arx and Buser attempted to regenerate severe horizontal bone atrophy using autogenous block grafts (symphysis or retromolar) covered with an organic bovine bone mineral (ABBM) and a bioabsorbable collagen membrane in 42 patients. They concluded that the use of block graft with ABBM filler and a collagen membrane demonstrated successful horizontal ridge augmentation with high predictability.¹⁶

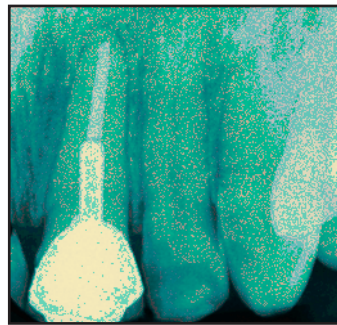


Figure 9. Radiographic demonstration of the traumatized fracture site.

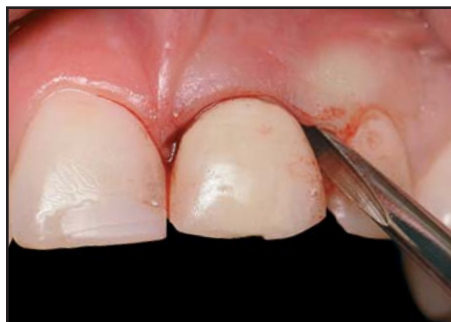

Figure 10. Atraumatic extraction of the maxillary left central incisor was facilitated.

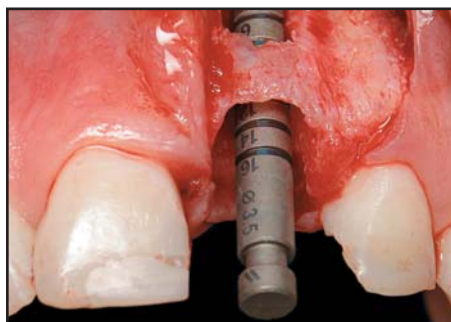


Figure 11. Facial view showing the presence of an apical fenestration.

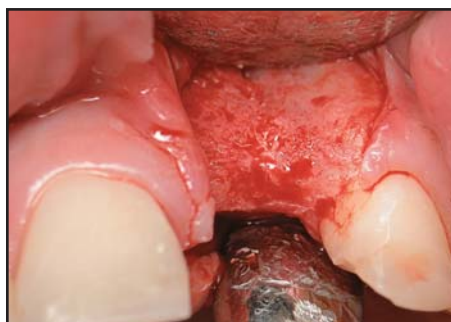

Figure 12. Facial view demonstrating sufficient bone volume at six months surgical re-entry.

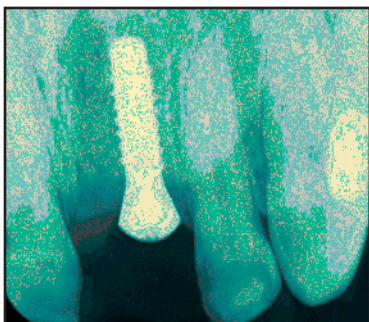


Figure 13. Radiographic image demonstrating the final placement of the dental implant.

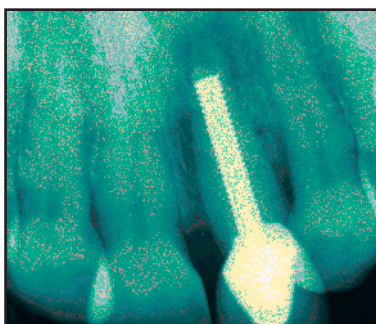


Figure 14. Case 3. Preoperative radiographic view of the maxillary left central incisor.

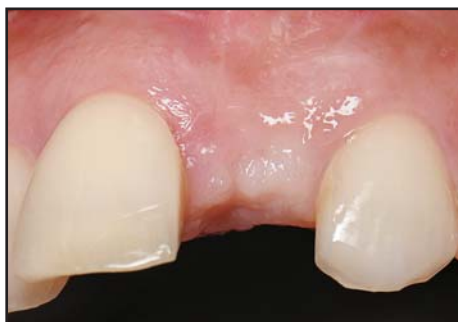

Figure 15. Facial view at six months, with sufficient ridge width present.

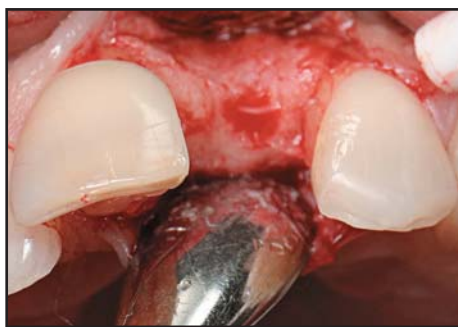

Figure 16. Facial demonstration of surgical re-entry at six months.

Case Presentations

In the current case series, an allograft with osteoinductive properties (ie, DynaBlast Paste, Keystone Dental, Burlington, MA) was used with a GBR resorbable collagen membrane (Bio-Gide, Osteohealth, Shirley, NY). This bone graft material was employed, as it was easy to manipulate and could be formed to adapt and augment the bony defect without dislodgement.

Case 1

A 62-year-old female patient with controlled hypertension presented with pain and exudate from a non-healing scar in the mandibular left central incisor region. This tooth exhibited signs of failed endodontic treatment or a possible root fracture. The tooth had been endodontically treated with an apicoectomy six months prior. A non-healed incision line (from endodontic surgery) was present on the facial aspect of tooth #24(31) (Figure 1). During surgery, the incision line was refined, and a full-thickness flap was reflected. A vertical root fracture was present, and the tooth was extracted. Extensive facial dehiscence was noted. The area was augmented with an allograft (ie, DynaBlast Paste, Keystone Dental, Burlington, MA), and a collagen barrier (Bio-Gide, Osteohealth, Shirley, NY) was placed over the graft material without the aid of tacks or sutures (Figures 2 and 3). The facial flap was periosteally released to attain tension free primary closure. The surgical site was sutured with 5-0 vicryl sutures (Ethicon, Cornelia, GA), which were removed at the two-week postoperative visit. Upon surgical re-entry at six months, adequate bone volume was present, and a 3.3 mm × 10 mm implant (SLA, Straumann, Andover, MA) was placed (Figures 4 through 7).

Case 2

A 22-year-old male patient with an unremarkable medical history presented with a vertical root fracture to his maxillary left first central incisor as a result of sports-related injury (Figures 8 and 9). The tooth was traumatically extracted, and extensive facial fenestration was observed (Figures 10 and 11). The area was augmented with an allograft (ie, DynaBlast Paste, Keystone Dental, Burlington, MA), and a collagen membrane (Bio-Gide, Osteohealth, Shirley, NY) was placed on the facial and occlusal aspect of the extraction socket, extending underneath the palatal gingiva. The facial flap was repositioned and no attempt was made to attain primary closure. The site was sutured with 5-0 Vicryl sutures (Ethicon, Cornelia, GA), which were removed at two weeks. The patient was instructed to clean the area with a chlorhexidine mouthrinse and cotton swabs for a

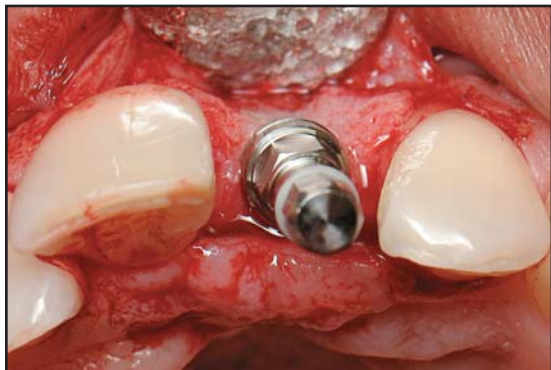

Figure 17. Incisal view of the dental implant immediately following placement.

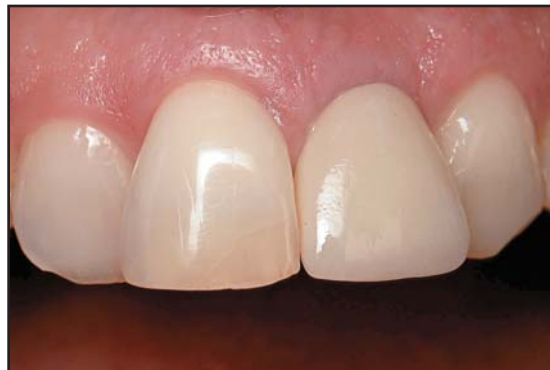

Figure 18. Clinical anterior view of the upper right and left central incisor restored.

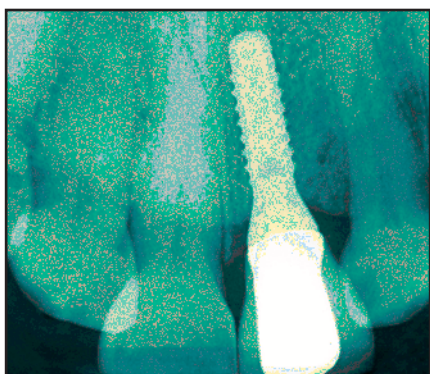


Figure 19. Radiographic view demonstrating successful implant placement and restoration.

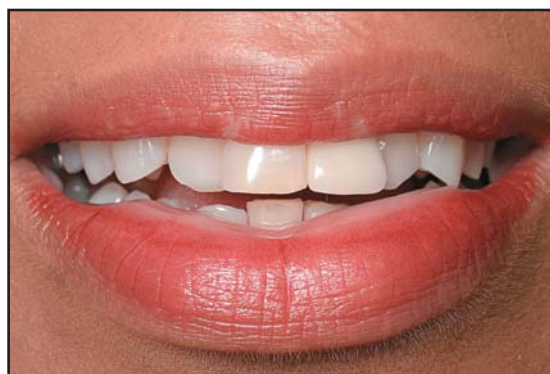

Figure 20. Facial view of the final aesthetic restoration with lips in repose demonstrates natural-looking contours.

period of six weeks. At six weeks, the epithelialization of the extraction site was complete. Upon surgical re-entry at six months, sufficient bone volume was present, and a 3.3 mm × 12 mm implant (SLActive, Straumann, Andover, MA) was placed (Figures 12 and 13).

Case 3

A 64-year-old female patient with an unremarkable medical history presented with pain in relation to the maxillary left central incisor. Clinical examination and a radiograph revealed the presence of a large post in tooth #9(21) and an area of periapical radiolucency (Figure 14). The tooth was extracted, and the socket was augmented with an allograft (ie, DynaBlast Paste, Keystone Dental, Burlington, MA). A collagen membrane (Bio-Gide, Osteohealth, Shirley, NY) was placed on the occlusal aspect of the extraction socket, extending beneath the facial and palatal gingiva. A figure eight 4-0 Vicryl suture (Ethicon, Cornelia, GA) was placed to keep the membrane secure. The suture was removed at two weeks. Sufficient ridge width was present at the

six-month assessment (Figure 15). Upon surgical re-entry, sufficient bone was present and a 3.3 mm × 12 mm implant (SLActive, Straumann, Andover, MA) was placed (Figures 16 and 17). The implant was then restored six months post placement (Figures 18 through 20).

Discussion

Clinical Considerations

Guided bone regeneration is a predictable means of restoring lost osseous tissue, resulting in successful implant survival.¹⁷ Although autogenous block grafts have been employed in GBR, there is associated neurological and vascular risk with their use.⁷ The use of allograft materials may minimize such risks. A premixed paste of demineralized bone matrix and mineralized cancellous chips, blended with a reverse-phase resorbable medium, is an ideal material, as it easily flows to fill the defect, and its viscosity reduces risk of dislodgement when placed. In addition to the bone allograft, the authors applied a collagen resorbable membrane to the site in each of these cases. This application may have served an advantage

over the use of non-resorbable membranes, since the latter may exhibit wound-line opening and infection due to bacterial colonization, thus jeopardizing the results of the regeneration.¹⁸

Case Selection

Bone volume is a significant predetermining factor that must be considered prior to implant placement. Careful selection criteria and clinical, as well as radiographic, evaluation is a prerequisite for proper treatment planning. The primary selection criteria included cases with alveolar ridge deformity or deficient bony walls at the time of extraction. Site preparation was completed to obtain sufficient bone for future implant placement. Furthermore, patients should be evaluated for any possible allergies to the grafting materials. The allograft employed in the aforementioned cases (ie, DynaBlast Paste, Keystone Dental, MA) was treated with polymyxin B sulfate, bacitracin, gentamicin, and iodine. Patients were assessed to ensure no possible allergic reactions to these materials prior to initiating treatment.

Indications and Contraindications

Guided bone regeneration is an invasive procedure and exhibits indications and contraindications as would any other treatment modality. The main indication for GBR includes an overall healthy patient with no pathologies present within the bony defect. It is generally believed that the standard implant length should be approximately 10 mm, in order to ensure the most predictable and favorable survival rates.¹⁹ Bone augmentation may be necessary to obtain sufficient bone volume for better implant survival.

Contraindications may include a medical condition that is not well controlled (ie, uncontrolled diabetes mellitus, cardiovascular disease, immunocompromising conditions, severe degenerative bone disease), a heavy smoking habit (ie, > 20 cigarettes per day), or pathology, localized active infection, deformity, or radiation therapy to the site to be augmented. Such conditions will predispose patients to postsurgical complications (eg, graft mass infection, loss of the augmented bone).

Conclusion

As the presented surgical cases and literature review demonstrated, guided bone regeneration enhanced the preservation of hard and soft tissue contour. There was no infection or surgical complication present, and predictable bone regeneration was obtained and verified at time of surgical re-entry. This allowed for good

implant positioning as well as improved aesthetic and functional results. Overall, GBR using an allograft paste demonstrated no adverse effects on clinical implant osteointegration and sufficient periodontal health was observed in all the cases.

Acknowledgment

The authors declare no financial interest in any of the products mentioned herein.

References

1. Lindhe J, Karring T, Lang NP. *Clinical Periodontology and Implant Dentistry*. 4th ed. Oxford, UK: Blackwell Munksgaard; 2003:667.
2. Schallhorn RG. Present status of osseous grafting procedures. *J Periodontol* 1977;48(9):570-576.
3. Schallhorn RG, Hiatt WH. Human allografts of iliac cancellous bone and marrow in periodontal osseous defects. II. Clinical observations. *J Periodontol* 1972;43(2):67-81.
4. Mellonig JT, Bowers GM, Bright RW, Lawrence JJ. Clinical evaluation of freeze-dried bone allografts in periodontal osseous defects. *J Periodontol* 1976;47(3):125-131.
5. Melcher AH. On the repair potential of periodontal tissues. *J Periodontol* 1976;47(5):256-260.
6. Buser D, Dula K, Belsler U, et al. Localized ridge augmentation using guided bone regeneration. I. Surgical procedure in the maxilla. *Int J Periodont Rest Dent* 1993;13(1):29-45.
7. Buser D, Dula K, Belsler U, et al. Localized ridge augmentation using guided bone regeneration. II. Surgical procedure in the maxilla. *Int J Periodont Rest Dent* 1995;15(1):10-29.
8. Fugazzotto PA, Shanaman R, Manos T, Shectman R. Guided bone regeneration around titanium implants: Report of the treatment of 1,503 sites with clinical reentries. *Int J Periodont Rest Dent* 1997;17(3):292,293-299.
9. Simion M, Dahlin C, Trisi P, Piattelli A. Qualitative and quantitative comparative study on different filling materials used in bone tissue regeneration: A controlled clinical study. *Int J Periodont Rest Dent* 1994;14(3):198-215.
10. Shanaman RH. A retrospective study of 237 sites treated consecutively with guided tissue regeneration. *Int J Periodont Rest Dent* 1994;14(4):292-301.
11. Dahlin C, Lekholm U, Becker W, et al. Treatment of fenestration and dehiscence bone defects around oral implants using the guided tissue regeneration technique: A prospective multicenter study. *Int J Oral Maxillofac Impl* 1995;10(3):312-318.
12. Coulthard P, Esposito M, Jokstad A, Worthington HV. Interventions for replacing missing teeth: Bone augmentation techniques for dental implant treatment. *Cochrane Database Syst Rev* 2003;(3):CD003607.
13. Simion M, Scarano A, Gionso L, Piattelli A. Guided bone regeneration using resorbable and nonresorbable membranes: A comparative histologic study in humans. *Int J Oral Maxillofac Impl* 1996;11(6):735-742.
14. Marinucci L, Lilli C, Baroni T, et al. In vitro comparison of bioabsorbable and non-resorbable membranes in bone regeneration. *J Periodontol* 2001;72(6):753-759.
15. Llambás F, Silvestre FJ, Caffesse R. Vertical guided bone regeneration with bioabsorbable barriers. *J Periodontol* 2007;78(10):2036-2042.
16. van Arx T, Buser D. Horizontal ridge augmentation using autogenous block grafts and the guided bone regeneration technique with collagen membranes: A clinical study with 42 patients. *Clin Oral Impl Res* 2006;17(4):359-366.
17. Nevins M, Mellonig JT, Clem DS 3rd, et al. Implants in regenerated bone: Long-term survival. *Int J Periodont Rest Dent* 1998;18(1):34-45.
18. Bunyaratavej P, Wang HL. Collagen membranes: A review. *J Periodontol* 2001;72(2):215-229.
19. Jaffin RA, Berman CL. The excessive loss of Branemark fixtures in type IV bone: A 5-year analysis. *J Periodontol* 1991;62(1):2-4.

CONTINUING EDUCATION (CE) EXERCISE No. 18



To submit your CE Exercise answers, please use the answer sheet found within the CE Editorial Section of this issue and complete as follows: 1) Identify the article; 2) Place an X in the appropriate box for each question of each exercise; 3) Clip answer sheet from the page and mail it to the CE Department at Montage Media Corporation. For further instructions, please refer to the CE Editorial Section.

The 10 multiple-choice questions for this Continuing Education exercise are based on the article "Guided bone regeneration using an allograft material: Review and case presentations," by Monish Bhola, DDS, MSD, Bassam M. Kinaia, DDS and Katy Chahine, DDS. This article is on Pages 487-493.

1. A bone graft material that contains bone forming cells is called:
 - a. Osteoinductive.
 - b. Osteopotent.
 - c. Osteoconductive.
 - d. Osteogenic.
2. When used around natural teeth, which bone graft may be associated with ankylosis and root resorption?
 - a. Allograft.
 - b. Autograft.
 - c. Xenograft.
 - d. Alloplast.
3. True regeneration may be derived from cells originating in:
 - a. Gingival epithelium.
 - b. Gingival connective tissue.
 - c. Periodontal Ligament.
 - d. Cementum.
4. During Guided Bone Regeneration (GBR) procedures, a comparison between resorbable and non-resorbable barriers revealed:
 - a. Resorbable barriers are superior.
 - b. Non-resorbable barriers are superior.
 - c. No difference.
 - d. All of the above.
5. According to Shanaman, comparison between various bone grafts for GBR demonstrated the following:
 - a. DFDBA was superior to FDBA.
 - b. FDBA was superior to DFDBA .
 - c. Both were equally superior.
 - d. An equal combination of both was superior.
6. According to Dahlin et al, results of GBR around fenestrations and dehiscence associated with dental implants:
 - a. Is directly proportional to operator experience.
 - b. Is a very predictable procedure.
 - c. Has a limited success rate.
 - d. Is only successful if autogenous grafts are utilized.
7. According to Fugazzato's study involving over 1500 implants, the success rate of immediate implants with GBR is:
 - a. 77%.
 - b. 87%.
 - c. 97%.
 - d. 67%.
8. Guided bone regeneration procedures are contraindicated in patients:
 - a. With uncontrolled diabetes.
 - b. Who are heavy smokers.
 - c. With localized active infections.
 - d. All of the above.
9. According to Jaffin and Berman, the minimal implant length recommended for long-term success is:
 - a. 6 mm.
 - b. 8 mm.
 - c. 10 mm.
 - d. 12 mm.
10. A disadvantage of using a non-resorbable barrier for GBR is:
 - a. Early degradation.
 - b. Bacterial colonization if exposed.
 - c. Allergic reaction.
 - d. Insufficient space maintenance.