To cite this article: Kinaia BM, et al. Supernumerary tooth autotransplantation to replace missing maxillary central incisor using three-dimensional replica: A 6-year follow-up. International Orthodontics (2022), https://doi.org/10.1016/j.ortho.2022.100635

International Orthodontics 2022; xx: xxx

Websites:
www.em-consulte.com
www.sciencedirect.com

Case report

# Supernumerary tooth autotransplantation to replace missing maxillary central incisor using three-dimensional replica: A 6-year follow-up

Bassam M. Kinaia [1,2], Dalia F. Hasso [1], Lidya Jirjis [1], Jonathan S. Zora [1], Khashayar Azimi [1], Lena Akkad [1], Kiran Agarwal [3], Ghabi Kaspo [2], Anthony L. Neely [1], Riyad Al-Qawasmi [1]

Available online:

1. University of Detroit Mercy School of Dentistry, Division of Graduate Studies, Detroit, MI, USA
2. Private practice, MI, USA
3. Private practice, MN, USA

**Correspondence:**
**Bassam M. Kinaia**, University of Detroit Mercy Detroit, Division of Graduate Studies, 2700 Martin Luther King Jr. Blvd., 48208-257 Detroit, MI, USA.
kinaiaperio@gmail.com, kinaiabm@udmercy.edu

Keywords
Autotransplantation
Bone graft
Guided tissue regeneration
Orthodontics
Periodontal
Supernumerary

## Summary

*Introduction >* Tooth autotransplantation is a viable surgical treatment option for patients with missing permanent teeth. Premolars are generally used for autotransplantation but often require extensive modifications. This case report evaluates the use of supernumerary tooth as an alternative option for premolar autotransplantation. This report shows successful supernumerary tooth autotransplantation with 6-year follow-up.

*Methods >* A 13-year-old male with non-contributory medical history was referred for a missing maxillary left central incisor (#9) and presence of a supernumerary tooth. The clinical and radiographic examination revealed presence of supernumerary tooth with similar dimensions to a central incisor. The treatment plan included autotransplantation of the supernumerary tooth to replace the missing central incisor (short-term) and future implant replacement of the autotransplanted tooth when jaw growth ceases (long-term). The patient and parents consented to treatment. A 3-D tooth replica was constructed based on CBCT analyses. Site #9 was prepared using split ridge technique to create a socket to house the 3-D replica. Upon achieving proper socket form, the supernumerary tooth was extracted and autotransplanted in the prepared socket. The supernumerary tooth was splinted, and the bite opened posteriorly using composite to eliminate any occlusal interferences.

*Results >* The patient was followed up clinically and radiographically. The autotransplanted supernumerary tooth integrated well within the newly created socket and remained functional at the 6-year follow-up.

*Conclusions >* The current case presents successful management of supernumerary tooth autotransplantation with 6-year follow-up. The results show stable periodontium with satisfactory functional and aesthetic results.

tome xx > 000 > xx 2022
https://doi.org/10.1016/j.ortho.2022.100635

To cite this article: Kinaia BM, et al. Supernumerary tooth autotransplantation to replace missing maxillary central incisor using three-dimensional replica: A 6-year follow-up. International Orthodontics (2022), https://doi.org/10.1016/j.ortho.2022.100635



## Introduction

Tooth autotransplantation is a practical treatment option to replace missing permanent teeth [1,2]. Autotransplantation was first reported in 1728 involving extraction of the donor tooth and inserted into an extraction socket or prepared recipient site [3]. Extracted premolars are often used for autotransplantation in patients undergoing orthodontics, but they often require extensive modifications [4]. The use of 3D CBCT imaging can allow construction of a 3D replica of the supernumerary tooth to facilitate more precise site preparation along with reduced extra-oral time during autotransplantation. Various case reports have documented successful autotransplantation with and without the use of these 3D replicas [5,6]. Controlled orthodontic forces in combination with autotransplantation result in a more favourable outcome because they allow for control of occlusion and promote regeneration of PDL to prevent ankyloses [7]. In addition to orthodontic evaluation, endodontic consultation should be considered to assess the apex of the supernumerary tooth and the potential need for endodontic therapy post autotransplantation. Therefore, careful interdisciplinary management of autotransplanted teeth result in stable periodontium with periodontal ligament (PDL) [8,9]. This case report presents an interdisciplinary approach of autotransplantation of a supernumerary tooth to replace a congenitally missing central incisor.

## Diagnosis and aetiology

A 13-year-old male with an unremarkable medical history presented to the Orthodontic Clinic at the University of Detroit Mercy. The patient was referred for a missing maxillary left central incisor (#9). The clinical and radiographic examinations revealed a deficient alveolar ridge (Site #9) with presence of a supernumerary tooth. The patient had a convex profile, bi maxillary protrusive, with an acute nasolabial angle and a shallow labiomental fold. Skeletally, the patient is class I ANB of 3.3 degrees with a Wits of −4.5 mm, with proclined and protruded U1's (U1's to SN is 118 degrees and U1's to NPo is 18 mm), and an IMPA of 90.5 degrees indicating normal lower incisors inclination, and an FMA of 22 degrees which classifies the patient as a normodivergent. Although AND indicates a class I patient, this patient's Wits is more accurate in this case, showing a class III skeletal relationship which was a challenge in treatment. Three-dimensional (3-D) computed tomography (CT) showed similar dimensions of the supernumerary tooth to a central incisor (*figure 1*, *table I*).

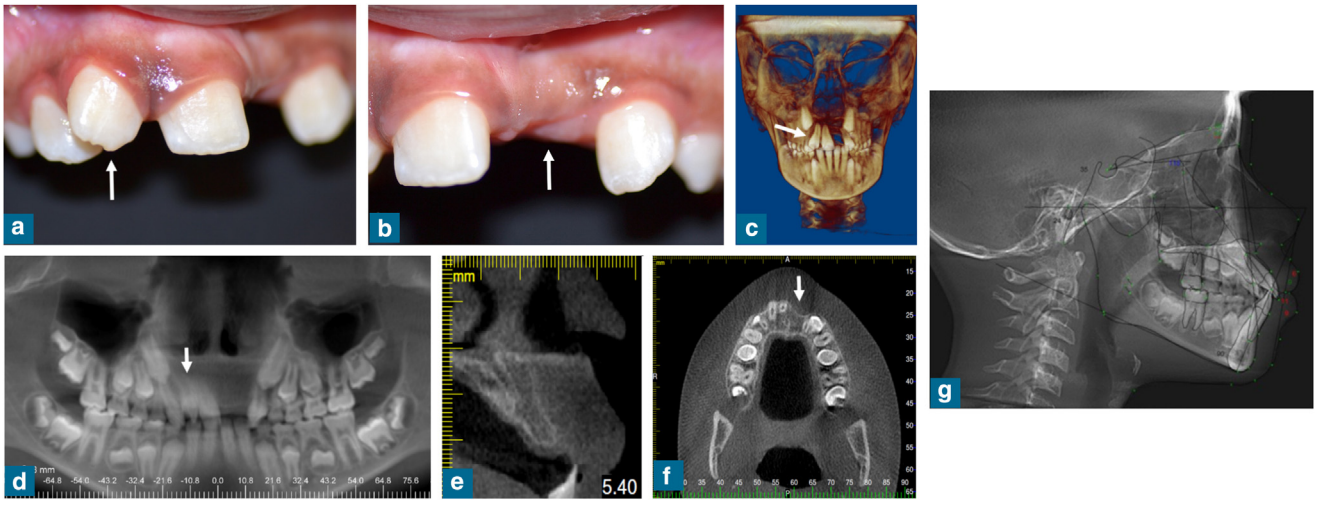


FIGURE 1

**Initial presentation: a) Facial view showing the supernumerary tooth (arrow) distal to tooth #8; b) Facial view showing the missing tooth #9 (arrow); c) The dimensions of the supernumerary tooth (arrow) are visualized by cone beam computed tomography rendering; d) Panoramic radiograph revealing edentulous ridge and supernumerary tooth (arrow); e) CBCT cross-section of the triangular shape edentulous ridge showing a narrow coronal aspect and a wider base making this a suitable candidate for the ridge split expansion technique; f) Transverse cross-section of the CBCT showing the buccal ridge deficiency (arrow) of the edentulous site. g) Lateral X-rays**

To cite this article: Kinaia BM, et al. Supernumerary tooth autotransplantation to replace missing maxillary central incisor using three-dimensional replica: A 6-year follow-up. International Orthodontics (2022), https://doi.org/10.1016/j.ortho.2022.100635





## Treatment Objectives

The treatment plan included autotransplantation of the supernumerary tooth to replace the missing central incisor and orthodontic treatment during the teenage years followed by dental implant replacement #9, if necessary, at adulthood. The patient and parents consented to treatment.

## Treatment alternatives

Treatment alternatives were discussed with the patient and parents. Options included extraction of supernumerary tooth and replacement of #9 with removable partial denture, Maryland fixed partial denture until adulthood. At adulthood, a new CT scan will be taken to assess bone volume for consideration of dental implant #9. The patient and parents consented to supernumerary tooth autotransplantation and orthodontic treatment.

## Treatment progress

Using the 3-D CT scan, a tooth replica was constructed through a rapid-prototyping machine[1] (2–3 mm longer than the autotransplanted tooth) to compensate for CT scan discrepancy [8]. The 3-D replica assists in preparing the recipient site to accommodate the autotransplanted tooth (*figure 2*).

Under local anaesthesia[2], the recipient site was prepared using a piezo surgery[3] split ridge technique (*figure 3ab*). The 3-D replica was tried and fitted into the newly created socket until proper socket form was achieved (*figure 3c*). Thereafter, the supernumerary tooth was carefully extracted and immediately autotransplanted in the new socket with simultaneous treatment with enamel matrix derivative[4], grafting with particulate cortico-cancellous allograft[5], and use of a resorbable collagen membrane[6] (*figure 3d*). The supernumerary crown and tooth #8 were reshaped and externally splinted to adjacent teeth (*figure 3f*). The flap was sutured using 4–0 resorbable sutures[7] (*figure 3g*). The bite was opened posteriorly using resin material[8] to eliminate any occlusal interferences (*figure 3h*).

Table I
**Comparison of cephalometric values before and after treatment.**

| Horizontal Skeletal | Norm (C) | Pre-treatment (05/2015) | Post-treatment (03/2021) |
|---|---|---|---|
| SNA (°) | 82 ± 3.5 | 88.6 | 93 |
| SNB (°) | 80 ± 3.4 | 85.3 | 89.7 |
| ANB (°) | 2 ± 1.5 | 3.3 | 3.3 |
| Wits (mm) | −1 ± 1.0 | −4.5 | −3.8 |
| Convexity (NA- NPO) (°) | 5 ± 3.0 | 10.5 | 10 |
| **Anterior Dental** | **Norm (C)** | **Pre-treatment (05/2015)** | **Post-treatment (03/2021)** |
| Holdaway (L1- NB: Pg- NB) (°) | 2 ± 1.0 | −2.6 | −1.3 |
| U1-SN (°) | 103 ± 5.5 | 114.7 | 115.3 |
| U1-NPo (mm) | 5 ± 2.0 | 18.1 | 12.2 |
| L1-NB (mm) | 4 ± 1.8 | 11.1 | 5.3 |
| FMIA (L1- FH) (°) | 65 ± 8.5 | 66.8 | 30.3 |
| IMPA (L1- MP) (°) | 90 ± 7.0 | 90.4 | 78.2 |
| **Vertical Skeletal** | **Norm (C)** | **Pre-treatment (05/2015)** | **Post-treatment (03/2021)** |
| FMA (MP- FH) (°) | 24 ± 4.5 | 22.8 | 21.5 |
| Y-Axis (°) | 67 ± 5.5 | 65.3 | 62.7 |
| SnGoGn (°) | 32.9 ± 5.2 | 30.9 | 30.31 |

[1] Rapid-prototyping machine and 3D Model, GuideMia Digital Dentistry, Los Alamitos, CA, USA.

[2] Lidocaine anesthetic, Benco Dental Supply Co., Pittston, PA, USA.
[3] Piezotome, Acteon, Mount Laurel, NJ, USA.
[4] Emdogain, Straumann, Basel, Switzerland.
[5] Puros cortico-cancellous allograft, Zimmer Biomet Dental, Palm Beach Gardens, Florida, USA.
[6] Bio-Gide, Geistlich, Princeton, NJ, USA.
[7] Resorbable sutures Vicryl, Medline Industries, IL, USA.
[8] Composite resin material, Ivoclar Vivadent, Amherst, NY, USA.

To cite this article: Kinaia BM, et al. Supernumerary tooth autotransplantation to replace missing maxillary central incisor using three-dimensional replica: A 6-year follow-up. International Orthodontics (2022), https://doi.org/10.1016/j.ortho.2022.100635



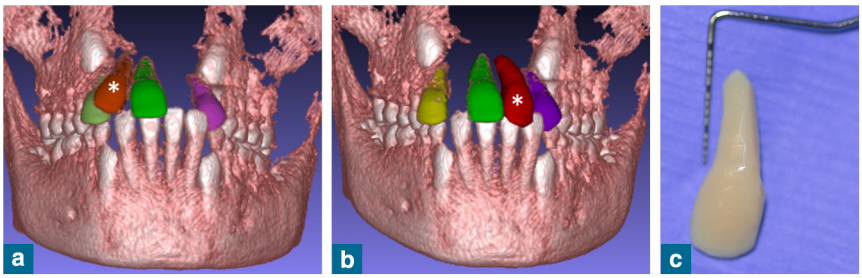


FIGURE 2

**Treatment planning phase using CBCT software to design the 3D replica and to evaluate available space for the recipient site. a) The 3D rendering with the highlighted supernumerary tooth (asterisk); b) simulation of the supernumerary tooth (asterisk) relocated to the edentulous site; and c) the 3D replica of the supernumerary tooth that will be used to for the try-in of the new socket for autotransplantation**


FIGURE 3

**Site preparation and autotransplantation: a) 4 mm palato-facial measurement of edentulous ridge of tooth #9; b) Split-ridge technique was used to expand the edentulous ridge using piezosurgery; c) Edentulous ridge in area of #9 post ridge split surgery and socket preparation with osteotomes; d) 3D replica was placed in the newly created socket; e) Supernumerary tooth was extracted and immediately autotransplanted into the socket and site was sutured; f) External fixation wire with composite was used to splint supernumerary tooth to adjacent teeth; g) Incisal edge of supernumerary tooth was adjusted. Composite was added to tooth #8 to create an interproximal contact and to add additional fixation; h) Occlusal stops (blue composite [asterisks]) were placed on mandibular second molars to eliminate occlusal contacts of transplanted supernumerary tooth**

To cite this article: Kinaia BM, et al. Supernumerary tooth autotransplantation to replace missing maxillary central incisor using three-dimensional replica: A 6-year follow-up. International Orthodontics (2022), https://doi.org/10.1016/j.ortho.2022.100635





## Treatment Results

The patient was followed up orthodontically and periodontally at 1 week, and 2, 3 and 6-months (*figure 4*), and 1, 3, and 6-years. At 6 months, the periapical radiograph reveals no sign of root resorption, and the patient reports no symptoms; however, an asymptomatic periapical lesion was present (*figure 5*). The autotransplanted tooth integrated well within the new socket and remained vital and functional up to the 3-year follow-up. The CBCT reveals evidence of normal periodontal ligament space (*figure 6*). At 3-years, a peri-apical radiolucency increased in size and an endodontic consultation was conducted. Subsequently, the autotransplanted tooth and #10 were treated endodontically and the radiolucency healed (*figure 7*). Further follow-ups at 3–4 years showed continued mandibular growth resulting in a skeletal class III relationship and orthodontic treatment was continued to maintain and restore proper occlusion. Additional follow-ups at 6 years, showed a periodontally stable supernumerary autotransplanted tooth with satisfactory functional results, normal periodontal ligament, normal periapical tissues, and aesthetic outcomes (*figure 8* and *figure 9*). At the end of treatment, patient's ANB is 3.3 degrees with a Wits of −3.8 mm, U1's to SN is 115 degrees which retroclined 5 degrees, U1's to NPo is 12 mm, IMPA is 78 degrees and an FMA of 21.5 degrees in comparison to initial values (*table I*).


FIGURE 5

**One week and two months follow-up at age 13 showing: a) Facial view of #9 one-week post-surgery; b) Lingual view of #9 one-week post-surgery showing external splinting; c) facial view of #9 4-week post-surgery showing the start of orthodontic treatment; d) Periapical radiograph of #9 two months post-surgery. Patient reported no symptoms with no indication of root resorption. However, an asymptomatic periapical lesion was noted**

FIGURE 4

**Initial patient presentation at the start of orthodontic treatment**

To cite this article: Kinaia BM, et al. Supernumerary tooth autotransplantation to replace missing maxillary central incisor using three-dimensional replica: A 6-year follow-up. International Orthodontics (2022), https://doi.org/10.1016/j.ortho.2022.100635




FIGURE 6

**3-year follow-up: a) Facial clinical view with continued orthodontic therapy; b) periapical radiograph revealing a large periapical radiolucency at apices of autotransplanted #9 and tooth #10 (compare to Figure 5d); c) Cross-sectional view of CBCT revealing the radiolucency at apex of #9. Note the normal appearance of the buccal and palatal periodontal ligament in cross-section. d) Endodontic treatment for # 9 and 10; e) Radiographic view one week after conventional root call fillings. Apical surgery was performed, and calcium sulfate graft was placed**


FIGURE 7

**The 6-year follow-up revealed that tooth #9 was periodontally stable, symptom free, and in full function. a) Facial view following completion of orthodontic therapy; b and c) Facial and occlusal views of #9, respectively, shows hard and soft tissue deficiencies with slight gingival recession; d and e) Periapical radiograph and cross-section of CBCT revealing normal periapical tissues with a minor void following osseous healing. Note that the periodontal ligament appears normal**

To cite this article: Kinaia BM, et al. Supernumerary tooth autotransplantation to replace missing maxillary central incisor using three-dimensional replica: A 6-year follow-up. International Orthodontics (2022), https://doi.org/10.1016/j.ortho.2022.100635



FIGURE 8
**Final patient presentation at 6-year follow-up**

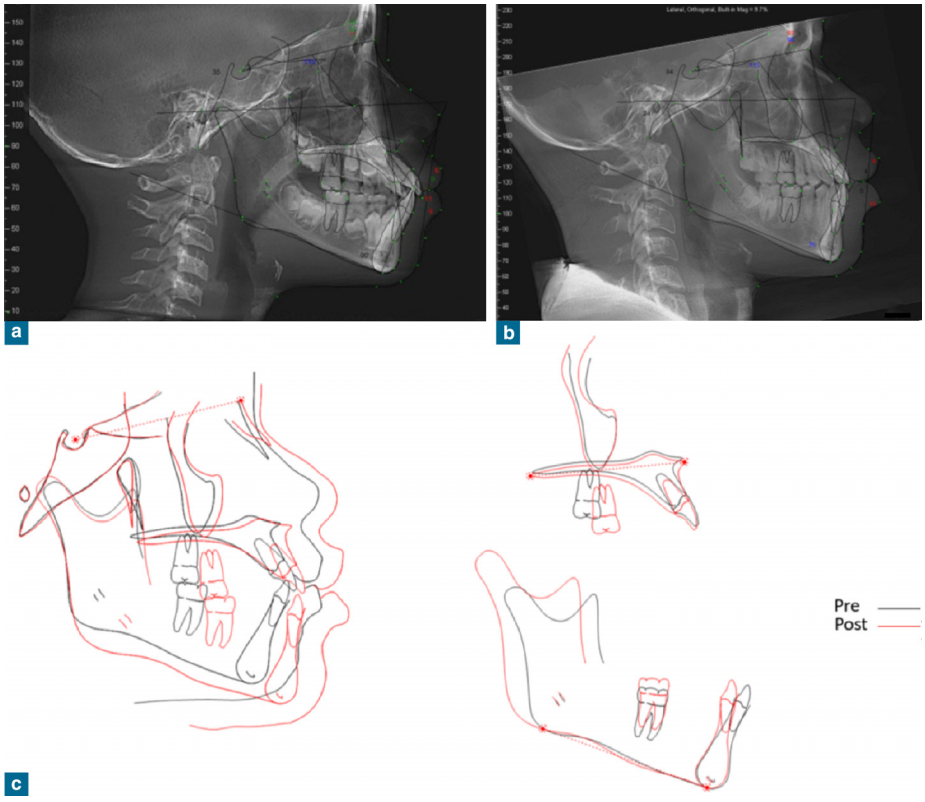


FIGURE 9
**Comparison of lateral X-rays and structural superimpositions before and after treatment**

## Discussion

Autotransplantation is a viable yet challenging treatment option for a patient who presents with missing teeth. An interdisciplinary approach involving orthodontic and periodontal teams is required to carefully select and plan tooth autotransplantation into an edentulous site. Patient selection criteria include appropriate clinical and radiographic assessment, fabrication of a 3D replica to reduce extra-oral surgical time [10], edentulous ridge preparation to accommodate the autotransplanted tooth and root development. Careful intra-operative surgical management is imperative to prevent PDL damage to the PDL, and to reduce extra-oral time of the autotransplanted tooth out of the socket to minimize possible ankylosis [8]. In this report, a 3-D replica was fabricated, and careful surgical management was used to minimize surgical time to enhance success. Additional factors that are favourable for periodontal ligament healing include: stage of root development, surgical difficulty, ease of handling and placement of graft, and presence/absence of ridge deficiency at the recipient site [11]. In the current report, a supernumerary tooth with an open apex was autotransplanted to replace a congenitally missing central incisor. If the supernumerary tooth presents with a closed apex, then endodontic treatment should be performed within 2 weeks of transplantation; however, if the apex is open then there is potential for revascularization and root length growth reducing need for endodontic therapy [10,12]. A review by Mendes and Rocha (2004) showed pulpal healing capability of 15% for mature closed apex teeth as compared to 96% of open apex immature roots after teeth autotransplantation [13]. In addition to assessment of pulpal vitality, routine follow-up is critical to evaluate the presence of post-surgical root resorption. As classified by Adreasen [14], the three types of root resorption that may result after this type of treatment include replacement resorption, inflammatory resorption, and surface resorption. Root resorption may be the consequence of poor intraoperative surgical management resulting in damage to the PDL fibers [15]. Further studies are required to investigate the impact of root resorption on overall tooth prognosis. In this report, endodontic therapy was required due to the presence of post-op peri-apical lesion at 3 years and the tooth was stable and in function at 6-years.

According to a systematic review by Machado (2016), the survival rate ranged from 75.3–91% with a meta-analysis effect size of 81% [16]. For a successful outcome, it is critical that pre-surgical assessment is completed, intra-operative surgical management is followed, while also using an interdisciplinary approach for appropriate case management.

## Conclusion

The current report presents successful management to autotransplant a supernumerary tooth with the assistance of orthodontic and endodontic treatment. The transplanted tooth integrated successfully in the new formed socket and remains functional at the 6-year follow-up with good aesthetic outcomes.

Bassam Kinaia: conceptualization, methodology, software, surgical procedure, supervision, writing-original draft, writing-reviewing and editing, visualization, investigation.

Dalia Hasso: writing-original draft, writing-reviewing and editing, visualization, investigation, project administration.

Lidya Jirjis: writing-original draft, writing-reviewing and editing, visualization, investigation.

Jonathan Zora: writing-original draft, writing-reviewing and editing, visualization, investigation.

Khashayar Azimi: writing-original draft, writing-reviewing and editing, visualization, investigation.

Lena Akkad: writing-original draft, writing-reviewing and editing, visualization, investigation.

Kiran Agarwal: investigation.

Ghabi Kaspo: resources, software.

Anthony Neely: conceptualization, methodology, software, supervision, writing-original draft, writing-reviewing and editing, visualization, investigation.

Riyad Al-Qawasmi: conceptualization, methodology, software, supervision.

**Funding:** this research did not receive any specific grant from funding agencies in the public, commercial, or not-for-profit sectors.

**Disclosure of interest:** the authors declare that they have no competing interest.

## References

[1] Demir T, Ates U, Cehreli B, et al. Autotransplantation of a supernumerary incisor as a replacement for fused tooth: 24-month follow-up. Oral Surg Oral Med Oral Pathol Oral Radiol Endod 2008;106. http://dx.doi.org/10.1016/j.tripleo.2008.06.004. e1-6.

[2] Fernandes PG, Novaes Jr AB, de Queiroz AC, et al. Ridge preservation with acellular dermal matrix and anorganic bone matrix cell-binding peptide P-15 after tooth extraction in humans. J Periodontol 2011;82:72–9. http://dx.doi.org/10.1902/jop.2010.100241.

[3] Cross D, El-Angbawi A, McLaughlin P, et al. Developments in autotransplantation of teeth. Surgeon 2013;11:49–55. http://dx.doi.org/10.1016/j.surge.2012.10.003.

[4] Fernandes S, Al Habibullah M, Nalam GS, et al. Think before you extract a case of tooth autotransplantation. BMJ Case Rep 2011;2011. http://dx.doi.org/10.1136/bcr.06.2011.4380. bcr0620114380..

[5] Dharmani U, Rajput A, Kamal C, et al. Successful autotransplantation of a mature mesiodens to replace a traumatized maxillary central incisor. Int Endod 2015;48:619–26. http://dx.doi.org/10.1111/iej.12347.

[6] Lee Y, Chang SW, Perinpanayagam H, et al. Kum K-Y Autotransplantation of mesiodens for missing maxillary lateral incisor with cone-beam CT-fabricated model and orthodontics Int Endod J 2014;47:896–904. http://dx.doi.org/10.1111/iej.12223.

[7] Kokai S, Kanno Z, Koike S, et al. Retrospective study of 100 autotransplanted teeth with complete root formation and subsequent orthodontic treatment. Am J Orthod Dentofacial Orthop 2015;148:982–9. http://dx.doi.org/10.1016/j.ajodo.2015.06.018.

[8] Tsukiboshi M. Autotransplantation of teeth: requirements for predictable success. Dent Traumatol 2002;18:157–80. http://dx.doi.org/10.1034/j.1600-9657.2002.00118.x.

[9] Lu L, Sun HF, Xue H, et al. Effects of orthodontic load on the periodontium of autogenously transplanted teeth in beagle dogs. J Zhejiang Univ Sci B 2013;14:1025–32. http://dx.doi.org/10.1631/jzus.b1300062.

[10] Verweij JP, van Westerveld KJH, Anssari Moin D, et al. Autotransplantation With a 3-Dimensionally Printed Replica of the Donor Tooth Minimizes Extra-Alveolar Time and Intraoperative Fitting Attempts: A Multicenter Prospective Study of 100 Transplanted Teeth. J Oral Maxillofac Surg 2020;78:35–43. http://dx.doi.org/10.1016/j.joms.2019.08.005.

[11] Kafourou V, Tong HJ, Day P, et al. Outcomes and prognostic factors that influence the success of tooth autotransplantation in children and adolescents. Dent Traumatol 2017;33:393–9. http://dx.doi.org/10.1111/edt.12353.

[12] Armstrong L, O'Reilly C, Ahmed B. Autotransplantation of third molars: a literature review and preliminary protocols. Br Dent J 2020;228:247–51. http://dx.doi.org/10.1038/s41415-020-1264-9.

[13] Mendes RA, Rocha G. Mandibular third molar autotransplantation–literature review with clinical cases. J Can Dent Assoc 2004;70:761–6.

[14] Andreasen JO. Relationship between surface and inflammatory resorprtion and changs in the pulp after replantation of permanent incisors in monkeys. J Endod 1981;7:294–301. http://dx.doi.org/10.1016/S0099-2399(81)80095-7.

[15] Tatli U, Kürkçü M, Cam OY, et al. Autotransplantation of impacted teeth: a report of 3 cases and review of the literature. Quintessence Int 2009;40:589–95.

[16] Machado LA, do Nascimento RR, Ferreira DM, et al. Long-term prognosis of tooth autotransplantation: a systematic review and meta-analysis. Int J Oral Maxillofac Surg 2016;45:610–7. http://dx.doi.org/10.1016/j.ijom.2015.11.010.